

SLT may compromise the corneal endothelium

Keith Ong

University of Sydney, Australia; Royal North Shore Hospital, Australia; Dalcross Adventist Hospital, Australia; Ryde Hospital, Australia

Abstract

Purpose: Whitish spots are sometimes noted in the corneal endothelium after Selective Laser Trabeculoplasty (SLT). One wonders whether this could be laser burns to the corneal endothelium. To evaluate the corneal endothelium after SLT, corneal specular microscopy was performed before and after SLT.

Method: 20 patients with open angle glaucoma, who had SLT in February-March 2012, had their corneal endothelium examined with specular microscopy before and after SLT.

Results: 4 of the 20 patients showed numerous dark patches/spots on specular microscopy photographs of corneal endothelium after SLT. These dark patches/spots were found to have resolved by one month. 6 of the 20 patients showed few dark patches/spots after SLT. 10 patients had no significant dark patches/spots after SLT.

Conclusion: The effect of SLT on the corneal endothelium is probably transient, and long-term effects probably negligible in normal corneas. However, in compromised corneas and corneas with pigment deposits on endothelium or reduced corneal endothelial transparency, there may be a risk of corneal endothelial compromise especially following repeated SLT. The results of this study highlight caution when deciding to do repeat SLT.

Introduction

Selective laser trabeculoplasty (SLT) is now a commonly performed laser procedure for the treatment of Open Angle Glaucoma (OAG). It has been shown to be effective with minimal or no damage to the trabecular meshwork¹. Most problems related to SLT are transient, such as transient corneal oedema, intraocular pressure rise and anterior chamber inflammatory reaction².

One of the reasons for SLT to be frequently offered as an alternative to glaucoma eye drops is the presumed absence of significant adverse effects.

After SLT, a variable number of whitish spots can sometimes be observed in the corneal endothelium with slit lamp biomicroscopy. Hence, a small study was designed to evaluate the corneal endothelium with a corneal specular microscope after SLT.

A variable minute amount of particles or cellular debris is also noted in the aqueous humour of the anterior chamber after SLT. The amount of debris seen in the aqueous humour often correlates with the amount of microbubble formation in the trabecular meshwork when doing SLT.

Correspondence: Keith Ong, 2 Railway Avenue, Eastwood NSW 2122, Australia.
E-mail: keithong@optusnet.com.au

Method

This is a prospective study of 20 patients with open angle glaucoma who had SLT in February-March 2012 by the author. Ellex Tango (Ellex Medical Pty Ltd, Adelaide, Australia) laser was used for the SLT. Power settings were titrated 0.3 to 0.9 mJ to achieve the reaction of a hint of microbubbles in 80% of laser shots. About 50 +5 laser shots to 180 degrees of meshwork were done.

Corneal specular microscopy was performed using the Tomey EM-3000 Corneal Specular Microscope (Tomey Corporation, Nagoya, Japan). The instrument was set to examine the central cornea. Corneal specular microscopy was done before and after SLT, and then repeated at 1 month after SLT. Patients who returned for SLT on the other eye had an additional corneal specular microscopy photograph taken

Results

The automated corneal endothelial cell counter of the Tomey EM3000 did not appear to be reliable in some situations when multiple dark spots/patches were seen, as there was sometimes an increase in the cell count even when there had been dropouts in the specular microscope photograph. Hence, it would be more appropriate to subjectively evaluate the specular microscope photographs than rely on the objective automated cell count. Furthermore, the corneal specular microscopy photographs showed that some patients have dark spots/patches pre-SLT. Hence, it was important to compare pre and post-SLT corneal specular microscopy photographs, when analysing for changes due to SLT. The specular microscopy photographs were graded into 3 categories: (1) no significant change (2) few: increase of <5 dark spots/patches, (3) numerous: increase of >5 dark spots/patches.

10 of the 20 patients showed no increase in dark spots/patches on corneal specular microscopy and did not have any white spots on slit lamp examination after SLT. (Figure 1)

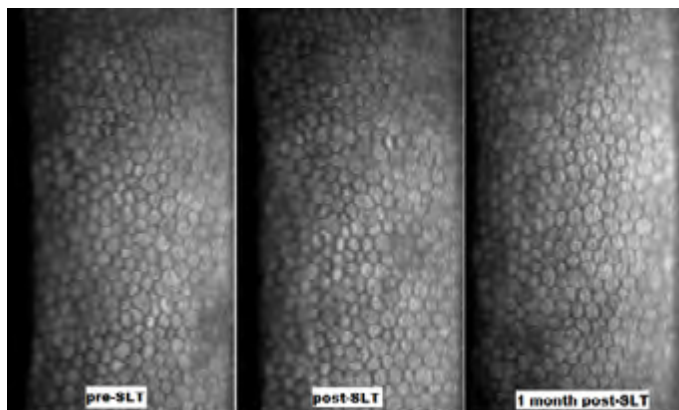


Figure 1: Patient from Group I with no change post-SLT

Six of the 20 patients showed an increase of less than 5 dark spots/patches on the corneal specular microscope photograph. By one month, all the dark spots/patches had resolved. (Figure 2)

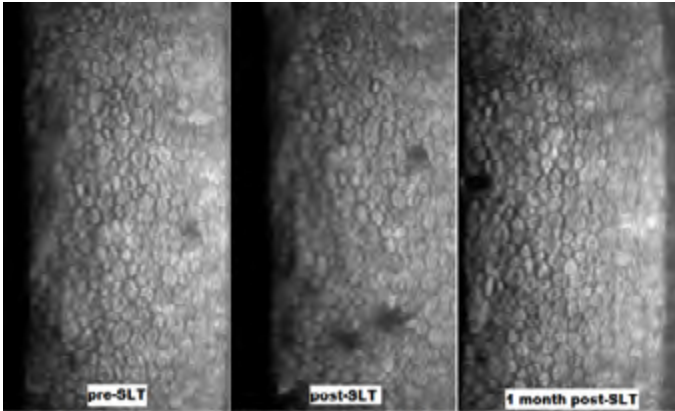


Figure 2: Patient from Group II with mild changes post-SLT

Four of the 20 patients showed an increase of more than 5 dark spots/patches on the corneal specular microscopy photographs, when compared with the pre-SLT photos. The number of these dark spots appears to correlate with the number of white spots seen in the corneal endothelium on slit lamp biomicroscopy. By one month, most of the dark spots/patches had resolved. (Figure 3)

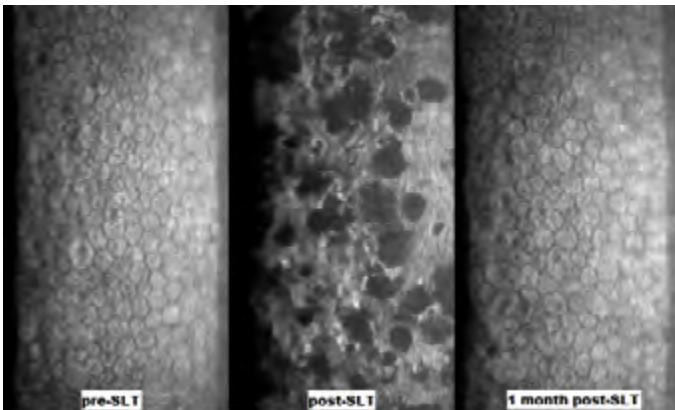


Figure 3: Patient from Group III with marked changes post-SLT

Discussion

Dark spots/patches in specular microscopy of the corneal endothelium are sometimes present in normal corneas. They may be due to oedema, subendothelial inflammatory cells, endothelial cell destruction/dropout or inflammatory deposits. These dark spots/patches may be more numerous in some conditions such as inflammatory eye disease, and some of these may resolve when the inflammatory

process resolves.⁵

The four patients who had a marked increase in dark spots/patches on specular microscopy of the corneal endothelium post-SLT were noted to have reduced corneal endothelial transparency and subtle pigmentation on the corneal endothelium pre-SLT. Slit lamp biomicroscopy also showed that they had more whitish spots in the corneal endothelium after SLT.

This finding agrees with previous clinical experience, which indicated that patients with more whitish spots on slit lamp microscopy after SLT also have more dark spots/patches in the corneal endothelium when examined with corneal specular microscopy. These corneas tend to have a less healthy looking endothelium with lower endothelial cell counts and may also have pigmentation on corneal endothelium pre-SLT. Hence, it is possible that the pigment could absorb some of the SLT energy and damage adjacent endothelial cells.

It is a surprise that about 50% of patients had corneal endothelial changes on specular microscopy after SLT. This may mean that repeated SLT may cause problems in the future.

The pigment could have come from pigment deposition after laser peripheral iridotomy or intraocular surgery, pigment dispersion syndrome or pigment associated with corneal guttatae. Hence, it is suggested that caution be exercised when considering to repeat SLT on patients with pigment on the corneal endothelium.

There are few instances of patients complaining of ocular discomfort and blurry vision after SLT, and this could be related to corneal oedema due to transient corneal endothelium dysfunction after SLT. Case reports of corneal oedema after SLT by Moubayed et al⁴ in 2009 and Regina⁵ in 2011 could be related to this.

There may also be white spots in the corneal epithelium on slit lamp examination. This appears to be more likely in patients who have subtle corneal opacities, patients with dry eyes and patients with ocular surface disease who get mild fluorescein staining. Putting pressure with the contact lens for SLT (Latina or 3-mirror) can also predispose to spots in the corneal endothelium and epithelium after SLT. This may be related to reduced corneal transparency when there is deformation of the corneal stroma.

Specular microscopy of the corneal endothelium of patients who have had YAG laser capsulotomy (1064 nm) did not show dark spots/patches. This may be due to the more focussed energy of the photodisruptive YAG 1064 nm laser compared to the 532 nm of SLT, as both are Q-switched; with the YAG laser being of 4 nsec duration⁵ and the SLT of 3 nsec duration⁶. However, with YAG laser iridotomy there may be white spots in the endothelium on slit lamp biomicroscopy and dark spots on specular microscopy when the cornea overlying the laser iridotomy is examined. This may be due to the site of focused energy being closer to the corneal endothelium with YAG laser iridotomy. Moreover, the energy setting of about 10mJ is higher in YAG laser iridotomy than the energy setting of 1.2 mJ used in YAG laser capsulotomy.

Laser retinal photocoagulation using 532 nm did not appear to show dark spots or patches of corneal endothelium on specular microscopy. However, with

532 nm laser retinal photocoagulation, there are sometimes white spots in the corneal epithelium, which may be due to burns to the corneal epithelium opacity absorbing the laser energy. It may be possible that the continuous wave laser of 0.1 second pulse used for laser retinal photocoagulation is less damaging to the corneal endothelium than the spike of 532 nm in the 3 nanosecond pulse of SLT. When analysing the energy spike of laser retinal photocoagulation, with settings of 400 mW and 400 micron spot size with 0.1 sec duration, the total energy delivered is 40mJ delivered in 0.1 sec, and the energy that passes through the cornea in a 3 nanosecond period would be $400\text{mW} \times 3 \times 10^{-9} \text{ sec} = 1200 \times 10^{-9} \text{ mJ} = 1.2 \times 10^{-6} \text{ mJ}$. This is much less than the energy spike of 0.3 to 0.9 mJ of 532nm delivered during SLT in 3 nanoseconds. Table 1 summarises the laser energy transmitted through cornea per nanosecond; comparing SLT laser, YAG laser capsulotomy and laser retinal photocoagulation.

Table 1: Comparison of laser energy transmitted through cornea per nanosecond

	Wavelength	Duration	Energy per nanosecond	Total Energy in 3 ns
SLT laser	532 nm	3 ns	0.1-0.3 mJ	0.3-0.9 mJ
YAG laser capsulotomy	1064 nm	4 ns	0.3 mJ	0.9 mJ
Retinal photocoagulation Laser	532 nm	0.1 s	0.4×10^{-6} mJ	1.2×10^{-6} mJ

Conclusion

The effect of SLT on the corneal endothelium is probably transient, and long-term effects likely to be negligible in normal corneas. The results of this study confirm clinical experience that the risk of corneal endothelium compromise can be predicted in some cases.

Hence, prior to performing SLT, the corneal endothelium should be examined closely with the slit lamp microscope for pigment deposition and corneal guttatae or compromise. In suspicious cases of corneal compromise, corneal specular microscopy would be helpful before and after SLT, as this may influence the decision to repeat SLT in the future.

It would be wise to minimise SLT laser shots, and make every shot effective with minimal hint of microbubbles. However, one has to avoid risking too high a power setting, which can increase the risk of a burn or scar to the trabecular meshwork. Hence, one needs to titrate and keep adjusting the power while doing SLT. It is worth noting that usually less power is required for SLT on inferior trabecular meshwork compared to superior trabecular meshwork; and remembering this could save some unnecessary trial shots to achieve the optimum setting.

When the dark patches of corneal endothelium on specular microscopy resolve, it is not known whether this is due to recovery of the possibly damaged endothelial

cells or due to migration of adjacent endothelial cells to cover the defects.

Clinical experience and this study suggests that in corneas with pigment on the corneal endothelium and compromised corneas, there may be long-term effects of corneal endothelial compromise, especially with repeated SLT procedures. A larger and longer-term study with histopathologic evaluation would be useful to evaluate this matter further.

References

1. Latina M, de Leon J. Selective Laser Trabeculoplasty. *Ophthalmology Clinics of North America* 2005;18:408-419.
2. Realini T. Selective laser trabeculoplasty: a review. *J Glaucoma* 2008;17(6):497-502.
3. Tomey. Tomey Corporation 2011; Available from: <http://www.tomey.com>.
4. Regina M, Bunya VY, Orlin SE, Ansari H. Corneal edema and haze after selective laser trabeculoplasty. *J Glaucoma* 2011;20(5):327-329.
5. Brooks AM, Grant G, Gillies WE: Reversible corneal endothelial cell changes in diseases of the anterior segment. *ANZ Journal of Ophthalmology* 1987;15:283-289.
6. Lindstrom RL. Why using a NewGeneration Nd:YAG laser matters with Premium IOLs. Using less energy is important. *Cataract & Refractive Surgery Today* June 2010:43-44.